

## Rare case of upper gastrointestinal bleeding in achalasia

Wei-Wei Zhang, Xiang-Jun Xie, Chang-Xin Geng, Shu-Hui Zhan

Wei-Wei Zhang, Xiang-Jun Xie, Chang-Xin Geng, Shu-Hui Zhan, Department of Gastroenterology, Municipal Hospital of Qingdao, Qingdao 266000, Shandong Province, China

**Author contributions:** Xie XJ and Zhan SH supervised the patient's diagnosis and treatment; Zhang WW wrote the manuscript; Geng CX revised the manuscript.

**Supported by A grant from the Qingdao Technology Fund.**

**Ethics approval:** The study was reviewed and approved by the Municipal Hospital of Qingdao Institutional Review Board.

**Informed consent:** All study participants, or their legal guardian, provided informed written consent prior to study enrollment.

**Conflict-of-interest:** None.

**Open-Access:** This article is an open-access article which was selected by an in-house editor and fully peer-reviewed by external reviewers. It is distributed in accordance with the Creative Commons Attribution Non Commercial (CC BY-NC 4.0) license, which permits others to distribute, remix, adapt, build upon this work non-commercially, and license their derivative works on different terms, provided the original work is properly cited and the use is non-commercial. See: <http://creativecommons.org/licenses/by-nc/4.0/>

**Correspondence to:** Wei-Wei Zhang, MD, Attending Doctor, Department of Gastroenterology, Municipal Hospital of Qingdao, Jiao-zhou Road, Qingdao 266000, Shandong Province,

China. [zhangwwapple@163.com](mailto:zhangwwapple@163.com)

Telephone: +86-532-88905629

Fax: +86-532-88905630

Received: August 20, 2014

Peer-review started: August 21, 2014

First decision: November 18, 2014

Revised: November 29, 2014

Accepted: January 9, 2015

Article in press: January 15, 2015

Published online: March 16, 2015

### Abstract

Achalasia is a prototypic esophageal motility disorder with complications including aspiration-pneumonia, esophagitis, esophageal-tracheal fistula, spontaneous rupture of the esophagus, and squamous cell carcinoma. However, achalasia is rarely associated with esophageal stones and ulcer formation that lead to upper gastrointestinal bleeding. Here, we report the case of a 61-year-old woman who was admitted to our department after

vomiting blood for six hours. Physical examination revealed that the patient had severe anemia and mild palpitation in the upper abdomen. CT revealed lower esophageal dilatation and esophageal wall thickening, and an emergency upper endoscopy showed that the esophagus was substantially expanded by a dark round stone, with multiple ulcers on the esophageal wall and a slit in the cardiac mucosa with a large clot attached. The patient's history included ingestion of 1 kg hawthorn three days prior. The acute upper gastrointestinal bleeding was caused by Mallory-Weiss syndrome associated with achalasia and an esophageal stone. For patients with achalasia, preventing excessive ingestion of tannins is crucial to avoid complications such as bleeding and rupture.

**Key words:** Achalasia; Esophageal stone; Mallory-Weiss syndrome; Upper gastrointestinal bleeding

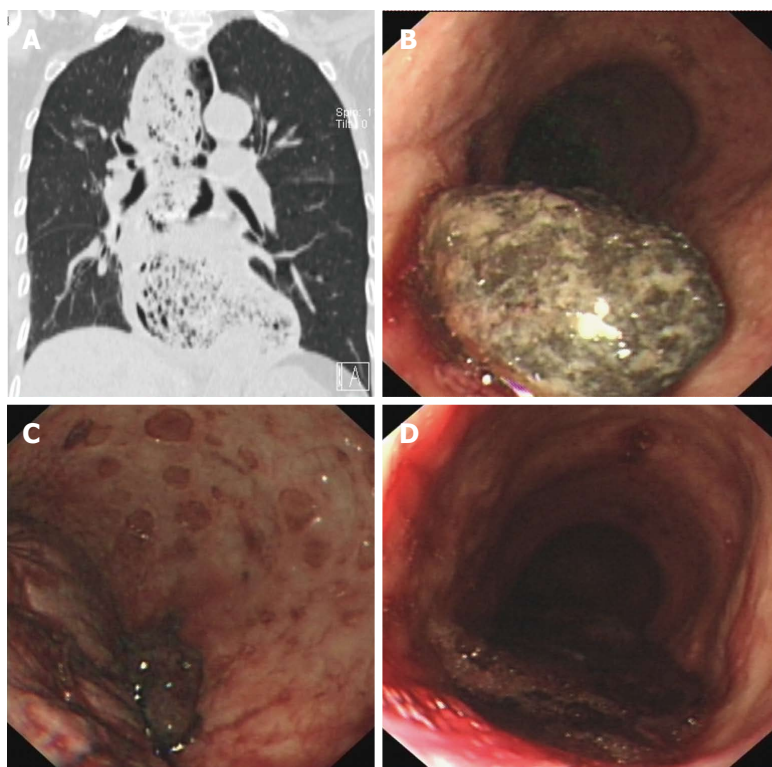
© **The Author(s) 2015.** Published by Baishideng Publishing Group Inc. All rights reserved.

**Core tip:** Achalasia is the prototypic esophageal motility disorder that leaves patients at risk for various complications. This is a rare report of long-term achalasia associated with esophageal stone and ulcer formation leading to upper gastrointestinal bleeding caused by Mallory-Weiss syndrome. This paper highlights the importance of avoiding excess tannin ingestion for patients with achalasia to prevent the development of complications such as bleeding and rupture.

Zhang WW, Xie XJ, Geng CX, Zhan SH. Rare case of upper gastrointestinal bleeding in achalasia. *World J Clin Cases* 2015; 3(3): 327-329 Available from: URL: <http://www.wjgnet.com/2307-8960/full/v3/i3/327.htm> DOI: <http://dx.doi.org/10.12998/wjcc.v3.i3.327>

### INTRODUCTION

Achalasia is the prototypic esophageal motility disorder



**Figure 1** CT and endoscopy imaging. A: CT showed lower esophageal dilatation and esophageal wall thickening; Upper endoscopy revealed; B: A large, dark round stone; C: Multiple ulcers on the esophageal wall; D: A slit in the cardiac mucosa with a large clot attached.

characterized by a hypertensive lower esophageal sphincter with incomplete relaxation upon swallowing, accompanied by aperistalsis of the esophageal body<sup>[1]</sup>. Patients with achalasia are at risk for developing complications such as aspiration-pneumonia, esophagitis, esophageal ulcers and bleeding, esophageal-tracheal fistula, spontaneous rupture of the esophagus, and squamous cell carcinoma<sup>[2]</sup>. The prevalence is 10 per 100000 in the United States, involving an equal distribution of men and women of all ages and from all ethnicities<sup>[3]</sup>. We report a rare case of upper gastrointestinal bleeding in a patient with achalasia that was associated with an esophageal stone, ulcer formation and Mallory-Weiss syndrome.

## CASE REPORT

A 61-year-old woman who complained of vomiting blood for six hours was admitted to our department. She experienced dizziness, palpitations, sweating, and fatigue, but did not present with fever, rash or jaundice. Her medical history revealed achalasia that had been present for 30 years, for which she had declined any treatment. When questioned, she reported ingesting 1 kg hawthorn within the past 3 d.

A physical examination indicated that the patient had severe anemia due to pale conjunctiva and nail beds, and mild palpitation in the upper abdomen. Routine blood tests showed: red blood cell count,  $1.34 \times 10^{12}/L$ ; hemoglobin, 41 g/L; white blood cell count,  $11.25 \times 10^9/L$ ; platelet count,  $150 \times 10^9/L$ ; blood urea nitrogen, 15.99 mmol/L; and creatinine, 98  $\mu\text{mol}/L$ . Lower esophageal dilatation and esophageal wall thickening

were revealed upon CT examination (Figure 1A). An emergency upper endoscopy was performed revealing substantial expansion of the esophagus by a dark round stone (Figure 1B), multiple ulcers on the esophageal wall (Figure 1C), and a slit in the cardiac mucosa with a large clot attached (Figure 1D). Endoscopic sprinkling hemostasis and injection of 2.5% sodium bicarbonate were applied to cease the bleeding and dissolve the stone.

## DISCUSSION

In achalasia, injury to the lower esophageal sphincter neurons and the loss of the main functional inhibitory neurotransmitter result in a hypertensive sphincter that loses its ability to relax, leading to stenosis of cardia and lower esophagus expansion. Occasionally, patients will present with persistent food retention, and esophageal stone formation can occur in those who have ingested foods rich in tannins, such as hawthorn and persimmon. The pressure of stones can cause multiple ulcers and even upper gastrointestinal bleeding. The discomfort when swallowing and frequent nausea and vomiting can then lead to the development of Mallory-Weiss syndrome.

Currently, there are no curative treatments for achalasia cardia, rather palliative measures are provided, such as oral nitrates or calcium channel blockers, endoscopic pneumatic dilation, injection of sclerosant substances, or surgery<sup>[4-6]</sup>. However, complications such as bleeding and rupture can be prevented by avoiding excessive ingestion of tannins.

## COMMENTS

### Case characteristics

A 61-year-old female patient complained of vomiting blood for six hours.

### Clinical diagnosis

Acute upper gastrointestinal bleeding from Mallory-Weiss syndrome associated with achalasia.

### Laboratory diagnosis

Red blood cell count,  $1.34 \times 10^{12}/L$ ; hemoglobin, 41 g/L; white blood cell count,  $11.25 \times 10^9/L$ ; platelet count,  $150 \times 10^9/L$ ; blood urea nitrogen, 15.99 mmol/L; creatinine 98  $\mu\text{mol}/L$ .

### Imaging diagnosis

CT showed lower esophageal dilatation and esophageal wall thickening. Upper endoscopy revealed a large round stone causing substantial expansion of the esophagus and multiple ulcers on the esophageal wall. A slit in the cardiac mucosa was observed with a large clot attached.

### Treatment

Endoscopic sprinkling hemostasis and injection of 2.5% sodium bicarbonate were applied to cease the bleeding and dissolve the stone.

### Related reports

Although there are some reports of achalasia combined with esophageal intramural hematoma or esophageal varices, reports of achalasia combined with esophageal stones, ulcer formation and Mallory-Weiss syndrome are rare.

### Term explanation

Achalasia is characterized by esophageal aperistalsis and impaired relaxation of the lower esophageal sphincter.

### Experiences and lessons

This report not only presents a rare case of upper gastrointestinal bleeding associated with achalasia, but also aims to inform patients with achalasia to avoid excessive ingestion of tannin-rich foods to prevent related complications.

### Peer-review

This is a very interesting manuscript reporting a rare case of upper gastrointestinal bleeding as a result of long-term achalasia associated with esophageal stones.

## REFERENCES

- 1 **Rohof WO**, Hirsch DP, Kessing BF, Boeckxstaens GE. Efficacy of treatment for patients with achalasia depends on the distensibility of the esophagogastric junction. *Gastroenterology* 2012; **143**: 328-335 [PMID: 22562023 DOI: 10.1053/j.gastro.2012.04.048]
- 2 **O'Neill OM**, Johnston BT, Coleman HG. Achalasia: a review of clinical diagnosis, epidemiology, treatment and outcomes. *World J Gastroenterol* 2013; **19**: 5806-5812 [PMID: 24124325 DOI: 10.3748/wjg.v19.i35.5806]
- 3 **Fei L**, Rossetti G, Moccia F, Cimmino M, Guerriero L, Romano G, Pascotto B, Orlando F. Definition, incidence and etiology: what's new in the 21st century? *Ann Ital Chir* 2013; **84**: 489-494 [PMID: 24141199]
- 4 **Moretó M**, Ojembarrera E, Barturen A, Casado I. Treatment of achalasia by injection of sclerosant substances: a long-term report. *Dig Dis Sci* 2013; **58**: 788-796 [PMID: 23179151 DOI: 10.1007/s10620-012-2476-x]
- 5 **Meireles OR**, Horgan S, Jacobsen GR, Katagiri T, Mathew A, Sedrak M, Sandler BJ, Dotai T, Savides TJ, Majid SF, Nijhawan S, Talamini MA. Transesophageal endoscopic myotomy (TEEM) for the treatment of achalasia: the United States human experience. *Surg Endosc* 2013; **27**: 1803-1809 [PMID: 23525881 DOI: 10.1007/s00464-012-2666-9]
- 6 **Bhayani NH**, Kurian AA, Dunst CM, Sharata AM, Rieder E, Swanstrom LL. A comparative study on comprehensive, objective outcomes of laparoscopic Heller myotomy with per-oral endoscopic myotomy (POEM) for achalasia. *Ann Surg* 2014; **259**: 1098-1103 [PMID: 24169175 DOI: 10.1097/SLA.0000000000000268]

**P- Reviewer:** Bax BE, Holtmann GJ, Munoz M **S- Editor:** Ji FF  
**L- Editor:** A **E- Editor:** Lu YJ





Published by **Baishideng Publishing Group Inc**

8226 Regency Drive, Pleasanton, CA 94588, USA

Telephone: +1-925-223-8242

Fax: +1-925-223-8243

E-mail: [bpgoffice@wjgnet.com](mailto:bpgoffice@wjgnet.com)

Help Desk: <http://www.wjgnet.com/esps/helpdesk.aspx>

<http://www.wjgnet.com>

