

## Case Reports

# Percutaneous Transhepatic Embolization as Treatment for Bleeding Ileostomy Varices

**Khaled K. Toumeh, Jeffrey D. Girardot, In W. Choo, James C. Andrews, Kyung J. Cho**

Department of Radiology, B1D 530 University of Michigan Hospitals, 1500 E. Medical Center Drive, Box 0030, Ann Arbor, MI 48109, USA

### Abstract

We report two patients with bleeding stomal varices following total colectomy and ileostomy. The varices were demonstrated by superior mesenteric angiography and percutaneous transhepatic mesenteric venography; dilated ileal veins drained via the stomal varices into abdominal wall veins. Bleeding from the stomal varices was treated by transhepatic embolization. The first patient required three transhepatic embolizations after recurrent bleeding due to recanalization of the embolized ileal vein and the development of collaterals from the adjacent ileal veins over a one-year period. The second patient died of respiratory failure 1 week after embolization. Neither patient developed mesenteric or stomal ischemia.

**Key words:** Enterostomal varices—Hemorrhage, therapy—Percutaneous transhepatic embolization, embolic material—Gelfoam—Ethanol—Coil—Portal hypertension—Complication

Massive hemorrhage from stomal varices is a rare but well-known complication of total colectomy with ileostomy in patients with cirrhosis and portal hypertension [1–9]. Most bleeding episodes are self-limited following conservative treatment. When the bleeding is massive or recurrent, surgical shunts have been performed [1, 6, 7, 9]. In this report we describe two patients with variceal bleeding from an ileostomy, in whom transhepatic portal vein catheterization was used to control the bleeding by embolization of the varices.

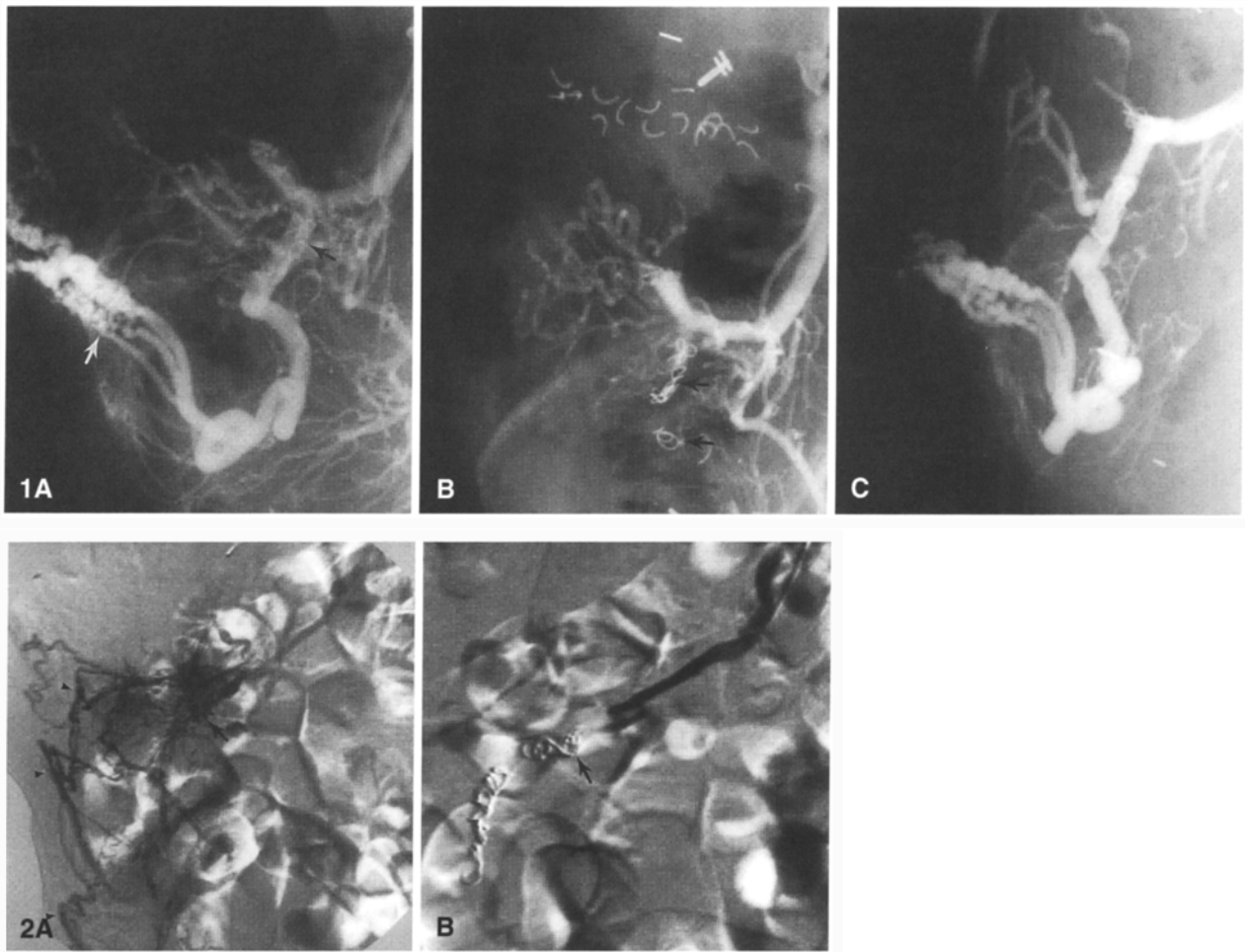
Correspondence to: K.J. Cho, M.D.

### Case Reports

#### Case 1

A 79-year-old woman was admitted with a 2-year history of recurrent bleeding from ileostomy varices. The bleeding began 1 year following total colectomy and ileostomy for colon carcinoma. She had a history of hepatitis. Physical examination was unremarkable except for evidence of bleeding from the distended submucosal veins in the ileostomy. Routine laboratory studies, including liver function tests, were normal. Tolazoline-enhanced indirect portography demonstrated portosystemic collaterals at the ileostomy from the ileocolic tributary of the superior mesenteric vein to the abdominal wall veins. The patient was not a candidate for a surgical portosystemic shunt and a transjugular intrahepatic portosystemic shunt (TIPS) [10] was unsuccessful due to the unfavorable hepatic venous anatomy. Therefore, percutaneous transhepatic portal catheterization was performed to obtain access to the varices for embolization. After transhepatic entry of the portal vein, a 5 Fr catheter was passed into the splenic vein. A splenoportogram showed patent splenic and portal veins with hepatopetal blood flow. Small esophageal varices were filled from the coronary vein. A superior mesenteric venogram showed a dilated ileal vein draining from the superior mesenteric vein to the ileostomy varices and then to the abdominal wall veins. The portal pressure was 26 mmHg, with a gradient (portal vein pressure minus vena cava pressure) of 15 mmHg. A Tracker-18 infusion catheter (Target Therapeutics, San Jose, CA, USA) was passed coaxially to the varices through the 5 Fr catheter positioned in the ileocolic vein. Embolization was then performed by placing microcoils into the ileocolic vein. A repeat mesenteric venogram following embolization showed occlusion of the varices. Upon completion of the embolization, a 3-mm coil was placed in the track near the hepatic capsule before complete removal of the catheter.

The patient developed recurrent bleeding from the stoma 10 days following the embolization. A repeat transhepatic mesenteric venogram showed recanalization of the ileal vein and varices that were occluded previously (Fig. 1A). The varices were embolized with absolute alcohol and Gelfoam pieces using the same coaxial catheter technique as before. A postembolization venogram showed occlusion of the varices (Fig. 1B). One year later, she developed recurrent bleeding from the recanalized ileostomy varices, which was again controlled by transhepatic embolization with alcohol, Gelfoam, and Gianturco coils (5 mm in diameter, Cook Inc, Bloomington, IN, USA) (Fig. 1C). The patient developed no clinical evidence of bowel ischemia. Two years have



**Fig. 1.** **A** Transhepatic mesenteric venogram with injection of contrast medium in the ileal collateral vein 10 days following embolization shows recanalization of the previously occluded collateral vein (black arrow) and stomal varices. The ileal vein drains from the superior mesenteric vein to the stomal varices and then to the abdominal wall veins through the submucosal veins (white arrow). **B** After embolization with ethanol, gelatin sponge, and microcoils, the collateral vein is occluded (arrows), and varices are no longer filled. **C** One year later, the patient had recurrent stomal bleeding. A repeat trans-

hepatic venogram demonstrated recanalization of the ileostomy varices.

**Fig. 2.** **A** Percutaneous transhepatic digital subtraction venogram of the ileal collateral vein shows ileostomy varices (arrow) and collaterals to the abdominal wall veins (arrowheads). **B** A repeat venogram following embolization with microcoils shows occlusion of the collateral vein (arrow). Ileostomy varices are no longer seen.

passed since the third embolization. There has been no recurrent bleeding.

### Case 2

A 70-year-old man was admitted to the Clinical Research Center to undergo his second hepatic arterial chemotherapy for diffuse hepatic metastases. Ten years before admission, he had total colectomy with ileostomy for colon cancer associated with ulcerative colitis. Laboratory studies revealed a hematocrit of 40%, platelets 204,000/mm<sup>3</sup> (normal, 200,000–400,000/mm<sup>3</sup>), and a prothrombin time of 11.6 sec (normal, 11.4–13.3 sec).

On the first day of hospitalization, the patient received flouxiridine 16 mg in 250 ml of 5% dextrose in water with 5000 units of heparin. Several hours later, he bled from his ileostomy; the bleeding ceased after compression. On the fifth day of hospitalization,

the bleeding recurred but the patient remained stable. Repeat laboratory studies yielded an hematocrit of 34%, platelets, 216,000/mm<sup>3</sup>, prothrombin time of 13 sec, and partial thromboplastin time of 42 sec (normal 21.3–28.9 sec). The patient was then started on propranolol 40 mg twice a day to reduce the portal hypertension. On the sixth day of hospitalization, he developed massive bleeding from the ileostomy and was resuscitated with intravenous fluids and 3 units of packed red blood cells. Two days following the last episode of bleeding, tolazoline-enhanced indirect portography showed a dilated ileal vein draining from the superior mesenteric vein to the ileostomy varices and then to the abdominal wall veins. A percutaneous transhepatic portogram showed patent splenic, superior mesenteric and portal veins, and a dilated ileal vein to the ileostomy. A digital subtraction venogram of the ileal collateral vein showed the ileostomy varices and collaterals to the abdominal wall veins (Fig. 2A). The portal blood flow was hepatofugal. The portal venous pressure was 29 mmHg. Microcoils were injected into the varices through a 3 Fr Tracker-18 catheter passed coaxially

through the 5 Fr catheter positioned in the ileocolic vein. A repeat venogram after embolization showed occlusion of the varices (Fig. 2B). The patient died of respiratory failure 1 week later.

## Discussion

Bleeding from enterostomal varices is a rare complication of total colectomy and ileostomy in patients with cirrhosis and portal hypertension. Such variceal bleeding is usually chronic and recurrent rather than massive. A variety of therapeutic methods have been used to control bleeding, including local compression, transfusion, ligation of varices, and stomal revisions (3–5, 8). Surgical shunts have been performed when the bleeding is life threatening or unresponsive to conservative managements. Surgical decompression of the portal venous system is effective in controlling and preventing variceal bleeding, but it may cause liver failure or hepatic encephalopathy.

To our knowledge, these are the only patients to have undergone transhepatic embolization for control of ileostomy stomal variceal bleeding. As shown in our first patient, recurrent bleeding may occur as a result of recanalization of the varices after embolization. Because distension of the feeding vessel secondary to elevated portal pressure may lead to recanalization of the varices, the variceal bed should be occluded with alcohol and its feeding vessels with larger coils. Our experience with our first patient and coronary vein embolization in others suggests that alcohol is a safe material in embolization of mesenteric and gastroesophageal varices.

Transhepatic variceal embolization as a means of controlling variceal bleeding was first described in 1974 by Lunderquist and Vang [11]. Although the method is effective in arresting acute variceal bleeding, its popularity has diminished due to a high incidence of recurrent bleeding and to the availability of endoscopic sclerotherapy. Follow-up studies have shown that recurrent bleeding was due to recanalization of the occluded varices and the development of new varices. Unlike the gastroesophageal varices that communicate with multiple feeding vessels, the ileostomy varices usually have a single feeding vessel from the superior mesenteric vein. We prefer to sclerose the varices initially with absolute ethanol and follow with Gelfoam and coil occlusion of the feeding vessel. Our technique of transhepatic portal catheterization is a slight modification of that described previously [11]. We prefer to puncture the portal vein transhepatically using a 22 gauge Chiba needle in the midaxillary line midway between the costophrenic angle and the inferior margin of the liver. Once the portal vein is punctured and the needle position in the portal vein is confirmed by the injection of contrast medium, a 0.018" Cope mandril

wire is passed through the needle to the main portal vein. Then a 4 Fr sheath/dilator is inserted, through which a 0.035" guidewire is passed to the portal vein. Over the guidewire, a 5 Fr angiographic catheter is then advanced into the portal vein. After a portogram with the injection of contrast medium into the proximal splenic or superior mesenteric vein, a 0.035" angled-glidewire (Medi-tech, Watertown, MA, USA) is used to catheterize the collateral tributary of the portal venous system. Superselective catheterization of the feeding vein with a 3 Fr coaxial catheter will allow occlusion of the collateral vein near the site of portosystemic communication and thus minimize the risk of bowel ischemia. The liver parenchymal tract is then plugged with coils.

The potential complications of transhepatic embolization include bleeding, bile leak, liver trauma, and portal vein thrombosis. In order to prevent bleeding from the puncture site, we routinely use either Gelfoam pieces or small coils to occlude the parenchymal track prior to removal of the transhepatic catheter. Liver trauma is rare when transhepatic punctures are made for coronary vein embolization. As portal vein thrombosis may result from overembolization, the progress of embolization and portal blood flow should be monitored during the embolization to prevent reflux of the emboli into the portal vein.

The results in our cases suggest that percutaneous transhepatic variceal embolization is a safe and effective approach to the treatment of bleeding stomal varices. However, as a high incidence of rebleeding is expected following the embolization, a TIPS procedure is the first choice to reduce recurrent variceal hemorrhage [10]. If this is not possible or desirable, the transhepatic approach represents a useful alternative treatment.

## References

1. Adson MA, Fulton RE (1977) The ileal stoma and portal hypertension: An uncommon site of variceal bleeding. *Arch Surg* 112:501–504
2. Ricci RL, Lee KR, Greenberger NJ (1980) Chronic gastrointestinal bleeding from ileal varices after total proctocolectomy for ulcerative colitis: Correction by mesocaval shunt. *Gastroenterology* 78:1053–1058
3. Graeber GM, Ratner MH, Ackerman NB (1976) Massive hemorrhage from ileostomy and colostomy stomas due to mucocutaneous varices in patients with coexisting cirrhosis. *Surgery* 79:107–110
4. Cameron AD, Fone DJ (1970) Portal hypertension and bleeding ileal varices after colectomy and ileostomy for chronic ulcerative colitis. *Gut* 11:755–759
5. Eade MN, Williams JA, Cooke WT (1969) Bleeding from an ileostomy caput medusae. *Lancet* 2:1166–1168
6. Fucini C, Wolff BG, Dozois RR (1991) Bleeding from peristomal varices: Perspectives on prevention and treatment. *Dis Colon Rectum* 34:1073–1078

7. Peck JJ, Boyden AM (1985) Exigent ileostomy hemorrhage. A complication of proctocolectomy in patients with chronic ulcerative colitis and primary sclerosing cholangitis. *Am J Surg* 150:153–158
8. Gundfest-Broniatowski S, Fazio V (1983) Conservative treatment of bleeding stomal varices. *Arch Surg* 118: 981–985
9. Cooper MJ, Mackie CR, Dhorajiwala J, Baker AL, Moossa AR (1981) Hemorrhage from ileal varices after total proctocolectomy. *Am J Surg* 141:178–179
10. LaBerge JM, Ring EJ, Gordon RL, Lake JR, Doherty MM, Somberg KA, Roberts JP, Ascher NL (1993) Creation of transjugular intrahepatic portosystemic shunts with the Wallstent endoprosthesis: Results in 100 patients. *Radiology* 187:413–420
11. Lunderquist A, Vang J (1974). Transhepatic catheterization and obliteration of the coronary vein in patients with portal hypertension and esophageal varices. *New Engl J Med* 291: 646–649