

Cholecystojejunostomy varices demonstrated by enteroclysis

J. T. Miller Jr., I. De Odorico, M. V. Marx

Department of Radiology, University of Michigan Hospitals, 1500 E. Medical Center Drive, Ann Arbor, MI 48109-0030, USA

Received: 12 February 1996/Accepted after revision: 19 June 1996

Abstract

Varices in unusual sites constitute a minor but significant cause of gastrointestinal bleeding in patients with liver disease. We report a case of varices across the anastomotic line between the jejunum and gallbladder after cholecystojejunostomy. Although such varices have been demonstrated by angiography, to our knowledge they have never been demonstrated by small bowel enema (enteroclysis). We report a case and describe the findings on enteroclysis.

Portal hypertension results in the development of portosystemic collaterals. The most clinically significant of these is that between the left gastric and short gastric veins, which anastomose with esophageal or paraesophageal veins. These in turn empty into the azygous venous system. These collaterals are responsible for bleeding esophageal varices, the major cause of death in patients with portal hypertension. Varices elsewhere in the gastrointestinal tract may also cause clinically significant bleeding. Atypically located varices may be difficult to recognize unless their presence is suspected clinically.

Case report

A 56-year-old male presented to a community hospital with fatigue, fever, and chills. He was anemic (hemoglobin, 6 g%). The fecal occult blood test was positive. He had a history of chronic pancreatitis and hepatic insufficiency related to a 40-year history of alcohol abuse. Eight years prior, he had an exploratory laparotomy for removal of a pancreatic pseudocyst, and during the surgery a cholecystojejunostomy was performed. During this admission, EGD, colonoscopy, up-

per gastrointestinal series, barium enema, tagged red blood cell scan, and mesenteric angiography were negative. He received 17 units of packed red blood cells. His overall condition improved, and he was discharged in stable condition.

One month later, the patient experienced bright red blood per rectum and required 30 units of packed red blood cells. He was discharged in stable condition. The etiology of his bleeding was uncertain.

Six weeks later, he was admitted to our institution for anemia (hemoglobin, 6.8 g%). Colonoscopy revealed large rectal varices. Gastroscopy revealed no varices or erosions in the esophagus or stomach. A tagged red blood cell scan did not demonstrate an active bleeding site. A mesenteric angiogram demonstrated superior mesenteric vein and portal vein occlusion in the region of the pancreatic head. Intrahepatic portal vein branches were filled via peripancreatic venous collaterals and varices across the cholecystojejunal anastomosis (Fig. 1).

Small bowel enema (enteroclysis) (Fig. 2) demonstrated multiple serpiginous filling defects at and near the anastomosis. These correspond to the angiographically demonstrated varices formed between the veins of the jejunal loop and the veins of the gallbladder. These varices were believed to be the source of the patient's bleeding. The patient was discharged in stable condition and is being considered for a portosystemic shunt.

Discussion

Portal hypertension causes collaterals to develop between the portal and systemic circulation, which decompress the portal venous system. Varices are thus formed. Varices in the distal esophagus and gastric fundus are by far the most common source of variceal bleeding in patients with portal hypertension [1]. Bleeding may also arise from varices located elsewhere in the gastrointestinal tract [2]. Atypically located varices are frequently overlooked in the differential diagnosis of gastrointestinal bleeding in patients with portal hypertension. Varices may be isolated or associated with esophagogastric varices. The prevalence of atypically located varices in patients with portal hypertension is not well established. Their prevalence is markedly increased in patients with por-

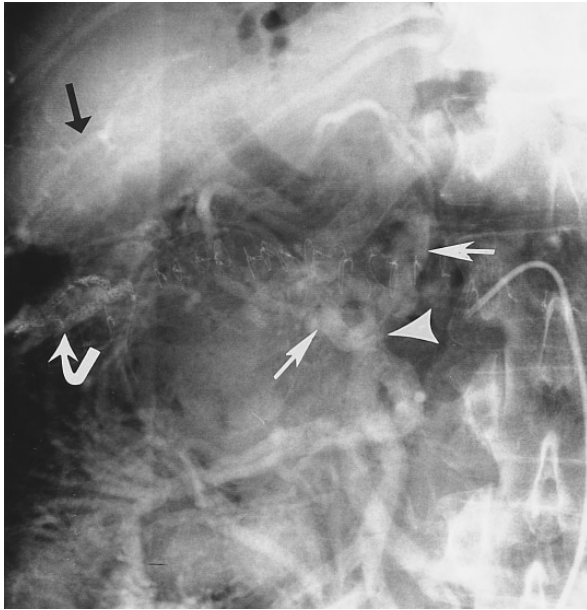


Fig. 1. Venous phase of superior mesenteric arteriogram. Catheter tip is in the superior mesenteric artery. The superior mesenteric vein is occluded centrally (*large arrowhead*). Collateral veins fill around the pancreatic head (*small arrows*). Varices fill at the cholecystojejunostomy staple line (*curved arrow*). Note reconstitution of intrahepatic portal vein branches (*black arrow*).

tal hypertension in whom abdominal or pelvic surgery has been performed [3]. Ectopic varices are mainly located in the duodenum, jejunum, ileum, colon, rectum, and at the stoma of an enterostomy [4]. Less frequently, the gallbladder, biliary tree, vagina, and bladder may be affected.

Duodenal varices represent about one-third of the reported cases of bleeding ectopic varices [3]. These have been demonstrated by barium swallow [4], and angiography [1, 5]. They are much more common in patients with extrahepatic rather than intrahepatic portal hypertension, especially if a previous history of abdominal surgery is present. Jejunal and ileal varices represent about one-third of the reported cases of bleeding ectopic varices [3] and are commonly seen in patients with prior history of abdominal or pelvic surgery. Duodenal varices have been demonstrated on enteroclysis [6] and angiography [1, 5, 7].

Colonic varices represent about one-fourth of the reported cases of bleeding ectopic varices [3] and are recognized on endoscopy and angiography [1, 4]. Rectal varices have been demonstrated on endoscopy and angiography [4]. Although hemorrhoids are varices located in the anus, they are distinct entities when compared with rectal varices. Hemorrhoids are not related to portal hypertension.

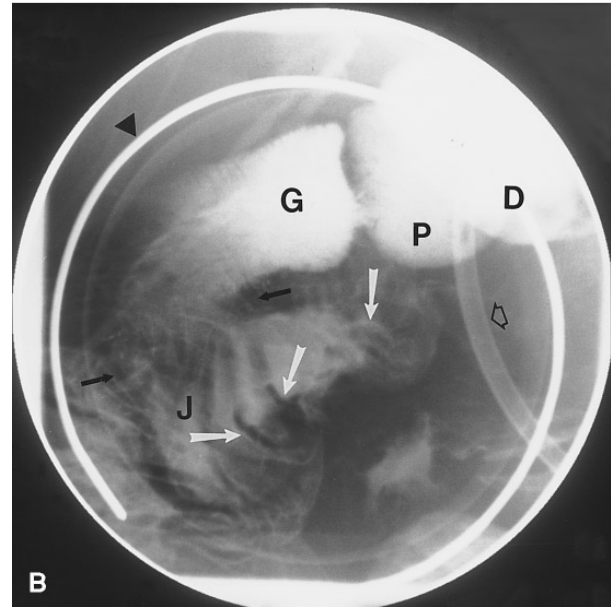
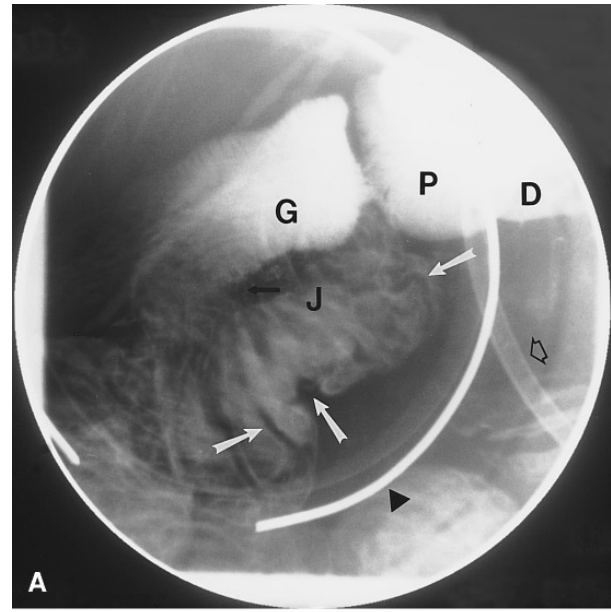


Fig. 2. A,B Digital spot views from small bowel enema (enteroclysis) demonstrate varicosities (*white arrows*) at cholecystojejunostomy (*black arrows*). *Open black arrow* = enteroclysis tube in second portion of duodenum, *black arrowhead* = marker in compression device, *G* = gallbladder with phrygian cap (*P*), *D* = duodenal bulb, *J* = jejunum.

Enterostomal varices develop when an ileostomy or colostomy brings the superior or inferior mesenteric network into contact with the abdominal wall venous network [3]. They are visualized at the venous phase of superior or inferior mesenteric angiography [4].

The common bile duct and gallbladder are potential sources for variceal formation in patients with portal

hypertension. The veins of the gallbladder serve as collateral channels between prehepatic and intrahepatic branches of the portal vein in patients with portal vein occlusion distal to the cystic vein. Ultrasound, computed tomography, magnetic resonance imaging [8], and angiography [9] have demonstrated gallbladder varices.

Salam et al. [1] first reported the angiographic demonstration of varices across the anastomotic line between the jejunum and gallbladder following cholecystojejunostomy in a patient with concomitant obstruction of the common bile duct and the portal vein. We were able to show angiographically confirmed cholecystojejunostomy varices by double-contrast study of the small bowel (enteroclysis).

In summary, atypically located varices are not difficult to recognize if their presence is suspected clinically. They constitute a minor but significant cause of gastrointestinal bleeding in patients with liver disease. Radiologists should be aware of the appearance of these varices with the growing use of enteroclysis.

References

1. Salam AA, Goldman M, Smith D, et al. Gastric, intestinal, and gallbladder varices: hemodynamic and therapeutic considerations. *South Med J* 1979;72:402–408
2. Lein BC, McCombs PR. Bleeding varices of the small bowel as a complication of pancreatitis: case report and review of the literature. *World J Surg* 1992;16:1147–1150
3. Lebec D, Benhamous JP. Ectopic varices in portal hypertension. *Clin Gastroenterol* 1984;14:105–121
4. Hamlyn AN, Morris JS, Lunzer MR, et al. Portal hypertension with varices in unusual sites. *Lancet* 1974;2:1531–1534
5. Rosen H, Silen W, Simon M. Selective portal hypertension with isolated duodenojejunal varices. *N Engl J Med* 1967;277:1188–1190
6. Agarwal D, Scholz FJ. Small bowel varices demonstrated by enteroclysis. *Radiology* 1981;140:350
7. Yuki N, Kubo M, Noro Y, et al. Jejunal varices as a cause of massive gastrointestinal bleeding. *Am J Gastroenterol* 1992; 87:514–517
8. West MS, Garra BS, Horii SC, et al. Gallbladder varices: imaging findings in patients with portal hypertension. *Radiology* 1991; 179:179–182
9. Charnangave JC, Thornhill B, Chuang VP, et al. Gallbladder varices: a potential collateral pathway in portal hypertension and portal vein occlusion. *Cardiovasc Intervent Radiol* 1984;7:247–250