



Case Report on Infectious Diseases and Acute Kidney Injury with Hemolytic Anemia.

Ms. Khushbu Meshram¹, Ms. Archana Taksande, Ms. Jaya Khandar, Ms. Prerana Sakharwade, Ms. Darshana Kumari, Ms. Sonali Kolhekar, Ms. Suwarna Ghugare.

¹Assistant Professor, Smt. Radhikabai Meghe Memorial College of Nursing, Sawangi (Meghe), Wardha. Datta Meghe Institute of Higher education and Research (Deemed To Be University) Maharashtra, India.

Email ID:- khushbupande86@gmail.com

ABSTRACT

Introduction:-

Portal hypertension is occurred when there is any disease condition of the liver like cirrhosis of liver, the liver undergoes changes in the structure. Acute kidney injury is the syndrome accompanied by slightly deterioration and severe impairment of kidney function. Pneumonia is an acute infection of the parenchyma of lung. Acute infectious hepatitis is an inflammation of liver caused by infectious agents. Leg abscess is necrosis of the leg tissues.¹(1)

Case Presentation

On February 27/2/23 a 13-year-old girl was brought to the A.V.B.R.H. Hospital's outpatient department with the main complaints being fever, abdominal distention, abdominal pain, breathing difficulties, foot swelling, appetite loss, chest pain, and light-colored urine and stool. In my patient according to investigations firstly there is acute hepatitis infection it results the abdominal distention due to that ultimately increases the pressure of liver circulatory system which is known as portal hypertension^{1,2}.(2)

Diagnostic Evaluation:-

Hemoglobin, total microcytic C count, total WBC count, total platelets count, urine albumin, creatinine, glucose, sodium, potassium, lymphocytes, HGB, HCT,MCV, MCH,ceruloplasmin test, ultrasonography of abdomen and Sawangi, tissue culture, color Doppler study, Arterial blood gas (ABG).Peripheral smear:- It shows mild anisopoikilocytosis hypochromic RBCs seen. Platelet mildly reduced Apc – 1,42,000 cell/cumm.

Intervention:-

Inj Augmenting 500 mg IV thrice a day, Inj amikacine 700 mg IV thrice a day (15mg/kg/day), Inj low molecular weight heparin 70mg subcutaneous IV once a day. Tab amlodipine 2.5 mg twice a day orally. Vitamin e 1 capsule OD (400 IU) etc.

Outcome: - after treatment patient shows better improvement in her health.

Conclusion

13 Year old female admitted in AVBR hospital Sawangi on dated 27/02/2023 with the chief complaint of swelling in feet's with pain since 7 days, fever since 5 days, abdominal distention since 5 days, and breathing difficulty since 3 days.

Keywords: Portal Hypertension, Acute kidney injury, pneumonia, acute infectious hepatitis, anisopoikilocytosis, ceruloplasmin test.

Introduction

In my patient according to investigations firstly there is acute hepatitis infection it results the abdominal distention due to that ultimately increases the pressure of liver circulatory system which is known as portal hypertension.

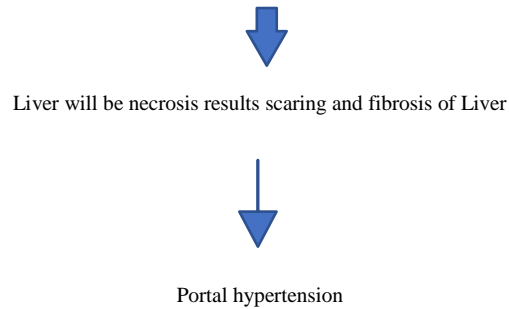
1. It normally occurs when patient with cirrhosis of liver and any changes undergoes in the structure of liver.
2. These changes usually lead to obstruction in the flow of blood in and out of the liver.

Portal hypertension is characterized by when there is an increased Venous pressure of Portal circulation, large collateral veins , ascites , splenomegaly and esophageal and gastric varices.³⁽³⁾

As a way of reducing pressure, in the body's system body develop alternate circulatory pathway which referred as collateral circulation. These collateral channels usually form in the lower part of esophagus, wall of abdomen (anterior) , parietal peritoneum and rectum.⁴⁽⁴⁾

Changes occur in the liver as follows:-

Inflammation of the liver



The phrase "acute kidney disease," or AKI, encompasses the whole spectrum of the condition, from mildly impaired kidney function to severe renal impairment. The fast loss of renal function in my patient was accompanied by an increase in serum creatinine and a decrease in urine output.⁵⁽⁵⁾

Intake	2121 ml
Output	1010 ml

Intake output charting of the patient.

The degree of systemic dysfunction varies; it may manifest as a lesser rise in serum creatinine levels or a decrease in urine production, which leads to the development of azotemia (the build-up of waste nitrogenous products in the blood, such as creatinine and urea nitrogen).⁶⁽⁶⁾

In addition to having a high death rate, AKI is possibly reversible and typically affects individuals with other illnesses that pose a serious threat to their lives. Hypovolemia, nephritic damage, intestinal nephritis, and decreased blood flow are some of the typical reasons. The death rate associated with AKI in patients in an intensive care unit is significant, ranging from 70% to 80%. An acute infection of the lung parenchyma is pneumonia. Among impoverished nations, pneumonia is a major cause of death, particularly among children. Around 900,000 children, the bulk of whom were under 2 years old, perished as a result of it in 2016, accounting for almost 16 percent of all under-five deaths worldwide. The development of penicillin and sulfa medicines proved essential for the treatment of pneumonia. Since then, there has been a notable advancement in the creation of antibiotics that can treat pneumonia.⁷⁽⁷⁾

But despite more modern antimicrobials, pneumonia continues to have high rates of morbidity and mortality.

- Three routes allow organisms that cause pneumonia to enter the lung:
 1. Aspiration of the nasopharynx's or oropharynx's natural flora. Many of the bacteria that cause pneumonia are common pharyngeal dwellers in healthy humans.
 2. Breathing in airborne microorganisms. Examples include pneumonias caused by *Mycoplasma* and fungi.
 3. Hematogenous spread from an initial illness somewhere else in the body. *Streptococci* and *Staphylococcus aureus* from infectious endocarditis are two examples.⁸⁽⁸⁾
 4. Acute hepatitis :- Many people with acute hepatitis don't experience any symptoms and may not even be aware that they are sick. On the other hand, some people may experience intermittent or persistent.

Anorexia, lethargy, nausea, vomiting, low-grade fever, skin rashes, diarrhea or constipation, malaise, weariness, myalgia's, arthralgia's, various flu-like symptoms, and right upper quadrant pain (induced by liver inflammation). Depending on the kind of hepatitis, the acute phase of viral hepatitis can persist anywhere between one and six months. The patient can have a loss of smell at this period and find meals repulsive. Smokers might not enjoy their cigarettes. Because the kidneys are excreting too much bilirubin, the urine may seem darker. The faeces will be light or clay colored if conjugated bilirubin cannot move from the liver into the intestines due to obstruction or inflammation of the bile ducts.⁹⁽⁹⁾

Jaundice is sometimes accompanied with pruritus, which is extreme generalized itching. Bile salts gather beneath the epidermis, which causes it to happen. The patient may find the pruritus intolerable. The convalescent phase starts as jaundice starts to subside. The convalescent phase might extend from a few days to many months, usually between two and four. Patients generally feel lousy and easily fatigued at this time. While splenomegaly (if existent) lessens during this time, hepatomegaly persists for a few weeks.¹⁰⁽¹⁰⁾ Leg abscess is caused in this patient by pricking of stone during the Play time and it ignored by her parents after that injury become increasing and forming fluid in the leg .

An abscess is a bodily fluid accumulation that is infected. In percutaneous abscess drainage, the infected fluid is removed or drained by inserting a needle or catheter through the skin into the abscess under the direction of imaging. Compared to open surgical drainage, it provides a quicker recovery. In order to drain the pus and clean the region, we treat the abscess by cutting a cut in the skin. The skin wound is not stitched shut; it is left open. This prevents Pus from re-infecting the region. The region was then covered with a dressing, which is a piece of material used to cover and protect a wound.¹¹⁽¹¹⁾

Patient information

A 13 year old female Ms. Pratiksha Moharle was taken to outpatient department of Acharya Vinoba Bhave Rural Hospital with the chief complaints of Fever , Abdominal distention , abdominal pain, difficulty in breathing , swelling in feet's ,loss of appetite, chest pain , yellowish discoloration of eyes light colored urine and stool.

Present medical history:

A female of 13 years old was brought to the outpatient department of A.V.B.R.H Hospital on 27/02/24 with the chief complaints of complaints of Fever, Abdominal distention , abdominal pain, difficulty in breathing , swelling in feet's ,loss of appetite, chest pain , yellowish discoloration of eyes light colored urine and stool.

Past medical history: Ms. Pratiksha Moharle a female patient of 13 years old from Bhari was admitted in AVBR hospital Sawangi Meghe Wardha. She was not have any past medical history like Bronchial Asthma, Tuberculosis, Thyroid Disorder and communicable diseases like AIDS.

Family history:

Ms Pratiksha Moharle belongs to a neutral family. My patient was diagnosed to have Portal hypertension with acute kidney injury with pneumonia with acute infectious hepatitis with left percutaneous leg abscess and in her family there was no one having any one of these disease. Only the patient was diagnosed with the diseases except him all the members in her family were healthy.

Patients intervention and outcome:

My patient was diagnosed as Portal hypertension with acute kidney injury with pneumonia with acute infectious hepatitis with left percutaneous leg abscess with when 13 years old from that time she was admitted to the hospital for time to time treatment of the disease.

Clinical Findings

Fever , Abdominal distention , abdominal pain, difficulty in breathing , swelling in feet's ,loss of appetite, chest pain , yellowish discoloration of eyes light colored urine and stool.

Etiology

Cirrhosis is a prevalent cause of portal hypertension in Western nations. However, in other regions of the world, the most typical cause of noncirrhotic portal hypertension is hepatic schistosomiasis and portal vein thrombosis. It is possible for portal hypertension to go unnoticed until difficulties arise.

Physical examination

While performing a head to toe examination of the patient, various anomalies were discovered. Her physical examination was lacking. She was drab and weak. All systems are normal except while doing abdominal examination abdomen was distended and Abdominal girth was 80 cm, abdominal varices are seen .Also in lower extremities pedal edema was seen and in the right leg there was the tumor which field with pus also swelling and redness of leg .body temperature was 38°C

DIAGNOSTIC ASSESSMENT:

Patient's investigation has been done that is

CBC (Complete Blood Count) :- having haemoglobin-6.4 gm. %, total RBC count is 2.83 million/cu mm, total WBC count is 43000 cu mm, creatinine level is 0.3 mg/dl, sodium level is 125mmol/l, albumin is 2.6g/dl, total bilirubin 2.5 mg/dl ,TLC is 56100 cell /cumm , segmented neutrophil 63 % , lymphocytes 6% , eosinophil 3% , basophil 00% . HCV is 67.9 fl , HCT is 19.3 % , HGB is 6.4 gm./dl .

Peripheral Smear: shows mild anisopoikilocytosis normocytic with microcytic hypochromic RBCs seen .Platelet mildly reduced APC – 142000 cells/cumm no hemoparocyte seen WBC series shows leukocytosis.

Other investigations –

- According to microbiology report –

Growth of staphylococcus aureus.

- Ultrasonography of Leg –

Localized fluid collection in subcutaneous measuring about 20 – 40 cc. In the medial of aspect of right ankle with multiple echogenic mobile echoes within localized abscess.

- Hepatomegaly, altered echotecture of liver, bulky bilateral kidney and decrease CMD
 - Color Doppler study –

Grade II renal parenchymal disease with normal renal vein Doppler.

Diagnosis

Portal hypertension with acute kidney injury with pneumonia with acute infection hepatitis with left percutaneous leg abscess.

THERAPEUTIC INTERVENTIONS

Injection cefotaxime 2.3 gm (150 mg/kg/day) iv thrice a day it is antibiotic with prevent infection, Vitamin D 60,000 IU once a day in one week, vitamin k 10 mg Stat, potassium chloride 5ml IV, calcium gluconate 5 ml IV 6 hourly in a day, O2 by CPAP, hepatic drip in 100 ml NS, Inj amikacine 700 mg IV once a day.

Discussion

A 13 yr old female child was brought to Acharya Vinoba Bhawe rural hospital Sawangi Meghe Wardha with chief complaint of swelling in feet's with pain 7 days , fever since 5 days, abdominal distention since 5 days , and breathing difficulty since 3 days. As narrated by mother patient was apparently alright 1 week back when she develop swelling on the right feet ,the swelling was sudden in onset aggravating on walking and relieve while on taking rest .it was followed by

Development of fever which was gradually in onset .the patient then developed abdominal distention which was insidious in on onset there was also yellowish discoloration of eyes as soon as she was admitted in AVBR hospital and started the treatment. Acute kidney injury (AKI) is the sudden failure of kidneys to function correctly. The result might be anything from a little decline in kidney function to total renal failure. AKI typically develops as a side effect from another severe illness. In contrast to what the name would imply, it is not the result of renal injury. This sort of kidney impairment usually manifests in older adults with other diseases including renal disease. Other illnesses that might lead to a sepsis, pneumonia, hepatitis, and other problems also arise as a result of renal failure. These are the outcomes of a weakened immune system linked to several medical diseases.¹²⁽¹²⁾

CONCLUSION

A 13-year-old youngster was taken to AVBR hospital with the main complaint of 7 days of discomfort and swelling in his feet, 5 days of fever, 5 days of stomach distention, and 3 days of breathing difficulties. The infant was found to have severe renal damage, pneumonia, acute hepatitis infection, and a left percutaneous leg abscess in addition to portal hypertension. In addition to her admission to the AVBR hospital, an investigation and treatment were conducted. She received therapy, recovered, and was released.

ETHICAL CLEARANCE:

Taken from institutional ethical committee.

SOURCE OF FINDING:

By myself.

REFERENCES:-

1. Watanabe K, Kimura K, Matsutani S, Ohto M, Okuda K. Portal hemodynamics in patients with gastric varices: A study in 230 patients with esophageal and/or gastric varices using portal vein catheterization. *Gastroenterology* [Internet]. 1988 Aug 1 [cited 2023 Nov 10];95(2):434–40. Available from: <https://www.sciencedirect.com/science/article/pii/001650858890501X>
2. Cleveland Clinic [Internet]. [cited 2023 Nov 10]. Portal Hypertension: Common Symptoms & Treatment. Available from: <https://my.clevelandclinic.org/health/diseases/4912-portal-hypertension>
3. Oliver TI, Sharma B, John S. Portal Hypertension. In: *StatPearls* [Internet]. Treasure Island (FL): StatPearls Publishing; 2023 [cited 2023 Nov 10]. Available from: <http://www.ncbi.nlm.nih.gov/books/NBK507718/>
4. Kenhub [Internet]. [cited 2023 Nov 10]. Portosystemic anastomosis. Available from: <https://www.kenhub.com/en/library/anatomy/portosystemic-anastomosis>
5. Acute kidney injury | Nature Reviews Disease Primers [Internet]. [cited 2023 Nov 10]. Available from: <https://www.nature.com/articles/s41572-021-00284-z>

6. Makris K, Spanou L. Acute Kidney Injury: Definition, Pathophysiology and Clinical Phenotypes. *The Clinical Biochemist Reviews* [Internet]. 2016 May [cited 2023 Nov 10];37(2):85. Available from: <https://www.ncbi.nlm.nih.gov/pmc/articles/PMC5198510/>
7. Solomon Y, Kofole Z, Fantaye T, Ejigu S. Prevalence of pneumonia and its determinant factors among under-five children in Gamo Zone, southern Ethiopia, 2021. *Front Pediatr* [Internet]. 2022 Dec 22 [cited 2023 Nov 10];10:1017386. Available from: <https://www.ncbi.nlm.nih.gov/pmc/articles/PMC9813436/>
8. Medscape Registration [Internet]. [cited 2023 Nov 10]. Available from: <https://emedicine.medscape.com/article/300157-overview?form=fpf>
9. Hepatitis B Foundation: Acute vs. Chronic Hepatitis B Infection [Internet]. [cited 2023 Nov 10]. Available from: <https://www.hepb.org/what-is-hepatitis-b/what-is-hepb/acute-vs-chronic/>
10. Bassari R, Koea JB. Jaundice associated pruritis: A review of pathophysiology and treatment. *World J Gastroenterol* [Internet]. 2015 Feb 7 [cited 2023 Nov 10];21(5):1404–13. Available from: <https://www.ncbi.nlm.nih.gov/pmc/articles/PMC4316083/>
11. Harclerode TP, Gnugnoli DM. Percutaneous Abscess Drainage. In: *StatPearls* [Internet]. Treasure Island (FL): StatPearls Publishing; 2023 [cited 2023 Nov 10]. Available from: <http://www.ncbi.nlm.nih.gov/books/NBK564356/>
12. MSD Manual Professional Edition [Internet]. [cited 2023 Nov 10]. Acute Kidney Injury (AKI) - Genitourinary Disorders. Available from: <https://www.msmanuals.com/en-in/professional/genitourinary-disorders/acute-kidney-injury/acute-kidney-injury-aki>